

Response Evaluation In Neurofibromatosis Schwannomatosis INTERNATIONAL COLLABORATION

- If sharing any data or information from these slides generated by the REiNS International Collaboration, please acknowledge the authors, group chairs, and specific working group.
- If using any information presented with a citation, please reference the primary source.

Radiation Risks of Imaging Studies

Response Evaluation in Neurofibromatosis and Schwannomatosis (REiNS) “Winter Meeting”

Shivani Ahlawat, MD

sahlawa1@jhmi.edu

Associate Professor of Radiology

The Russell H. Morgan Department of Radiology & Radiological Science,

The Johns Hopkins University



Response Evaluation In Neurofibromatosis Schwannomatosis
INTERNATIONAL COLLABORATION

Disclosures

- Grant/research support:
 - International Skeletal Society Seed Grant: 2018-2020
 - Department of Defense: 2017-2021
- Consultant:
 - Pfizer: 2017-2018



Objective

- To introduce concepts of radiation biology and radiation-related risks associated with radiologic imaging
- To appraise the relative risk of radiation associated with each imaging modality and their role in the context of scoliosis and osteoporosis related to peripheral nerve tumor syndromes



Radiation and Radiologic Imaging

- The use of ionizing radiation has inherent risks.
- Rapid technologic developments in radiology have had a direct positive impact on patient care.

The New York Times

THE CONSUMER

With Rise in Radiation Exposure, Experts Urge Caution on Tests



By Roni Caryn Rabin

June 19, 2007



Radiation Dose

Table 2. Radiation quantities and units

Quantity	Unit	Determination
Exposure	Coulomb per kilogram (C/kg), roentgen (R)	Measurement
Dose	Gray (Gy), rad	Multiply exposure by f-factor or a conversion factor
Equivalent dose	Sievert (Sv), rem	Multiply dose by a quality factor
Effective dose	Sv, rem	Multiply equivalent dose by a tissue weighting factor










- 1 Gy ~ energy deposition of 1 Joule/kg of tissue
- For x-rays & gamma rays: Radiation weighted factor = 1



Radiation Dose Estimates

	Per year***
Radon	2-3 mSV
Living in Colorado	1.5 mSv >> sea level
10 hour flight	0.03 mSv
Extremity (hand etc.)	< 0.001 mSV
DEXA scan	0.001 mSv
Chest x-ray	0.1 mSv
Mammogram	0.21 mSv
L spine x-ray	1.4 mSv
CT chest	6.1 mSv
CT ab/pelvis	7.7 mSv
CT spine	8.8 mSV
PET/CT Whole body	22.7 mSv

Radiation Dose to Adults
From Common Imaging Examinations

	Procedure	Approximate effective radiation dose (mSv)	Approximate comparable time of natural background radiation exposure
 ABDOMINAL REGION	Computed Tomography (CT) — Abdomen and Pelvis	7.7 mSv	2.6 years
	Computed Tomography (CT) — Abdomen and Pelvis, repeated with and without contrast material	15.4 mSv	5.1 years
	Computed Tomography (CT) — Colonography	6 mSv	2 years
	Intravenous Pyelogram (IVP)	3 mSv	1 year
	Barium Enema (Lower GI X-ray)	6 mSv	2 years
 BONE	Upper GI Study With Barium	6 mSv	2 years
	Lumbar Spine	1.4 mSv	6 months
 CENTRAL NERVOUS SYSTEM	Extremity (hand, foot, etc.) X-ray	< 0.001 mSv	< 3 hours
	Computed Tomography (CT) — Brain	1.6 mSv	7 months
	Computed Tomography (CT) — Brain, repeated with and without contrast material	3.2 mSv	13 months
 CHEST	Computed Tomography (CT) — Head and Neck	1.2 mSv	5 months
	Computed Tomography (CT) — Spine	8.8 mSv	3 years
	Computed Tomography (CT) — Chest	6.1 mSv	2 years
 DENTAL	Computed Tomography (CT) — Lung Cancer Screening	1.5 mSv	6 months
	Chest X-ray	0.1 mSv	10 days
	Dental X-ray	0.005 mSv	1 day
 HEART	Panoramic X-Ray	0.025 mSv	3 days
	Cone Beam CT	0.18 mSv	22 days
	Coronary Computed Tomography Angiography (CTA)	8.7 mSv	3 years
 MEN'S IMAGING	Cardiac CT for Calcium Scoring	1.7 mSv	6 months
	Non-Cardiac Computed Tomography Angiography (CTA)	5.1 mSv	< 2 years
 NUCLEAR MEDICINE	Bone Densitometry (DEXA)	0.001 mSv	3 hours
	Positron Emission Tomography — Computed Tomography (PET/CT) Whole body protocol	22.7 mSv	3.3 years
 WOMEN'S IMAGING	Bone Densitometry (DEXA)	0.001 mSv	3 hours
	Screening Digital Mammography	0.21 mSv	26 days
	Screening Digital Breast Tomosynthesis (3-D Mammogram)	0.27 mSv	33 days

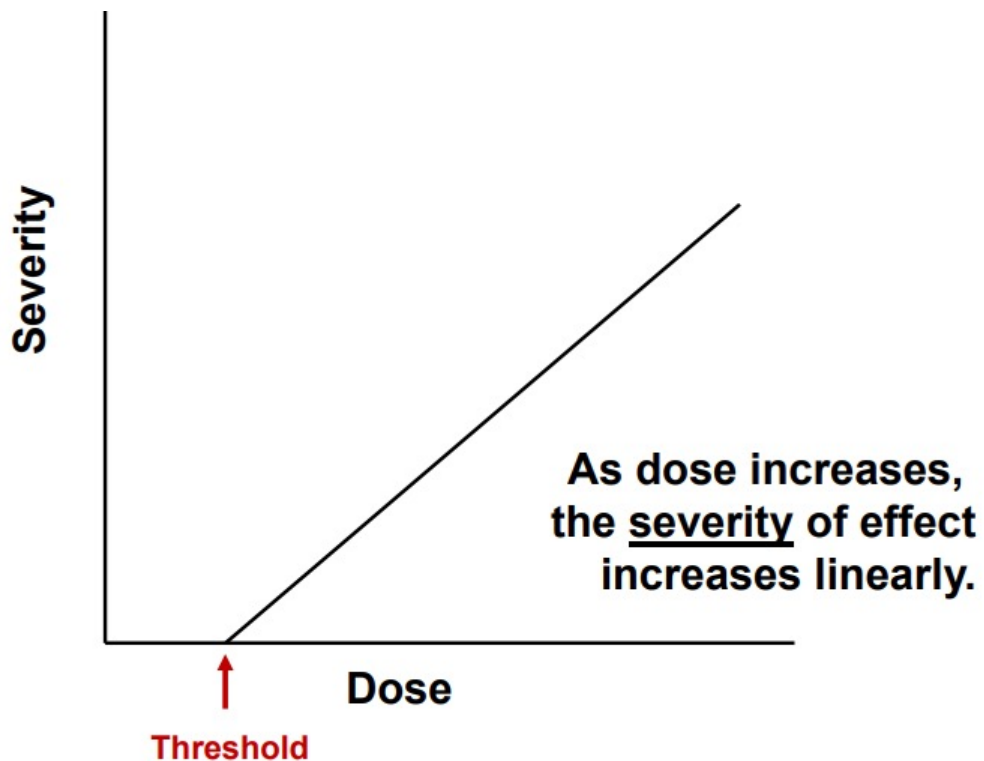


Radiation Health Effects: Early

- **Deterministic (non-stochastic)**

- Examples:

- Cataracts to lens of the eye
- Erythema (skin reddening):
- Sterility (temporary or permanent)
- Epilation (hair loss)

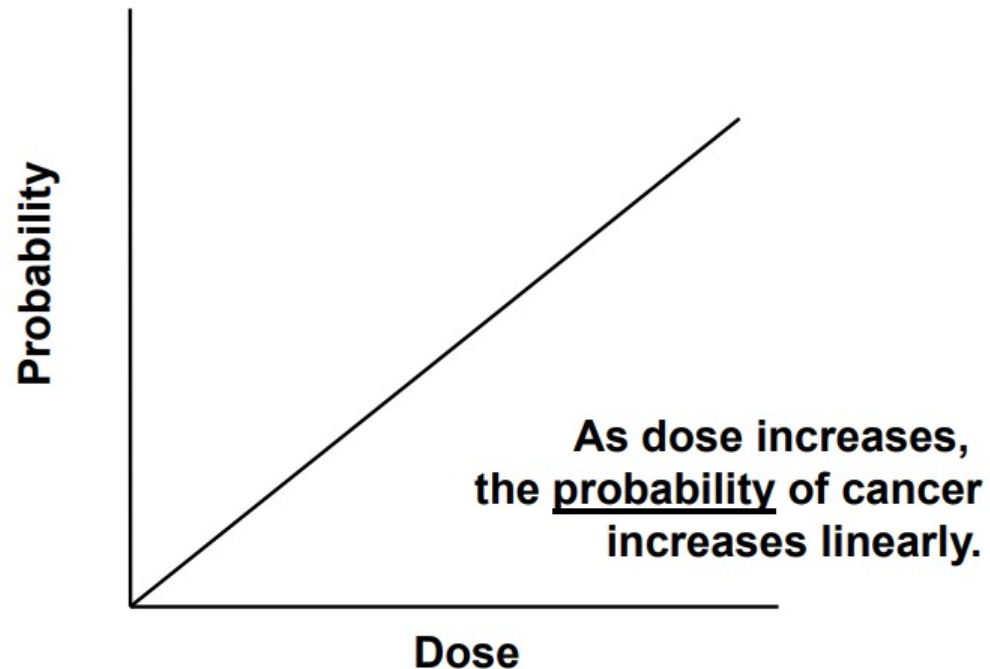


<https://www.nrc.gov/docs/ML1117/ML111711087.pdf>



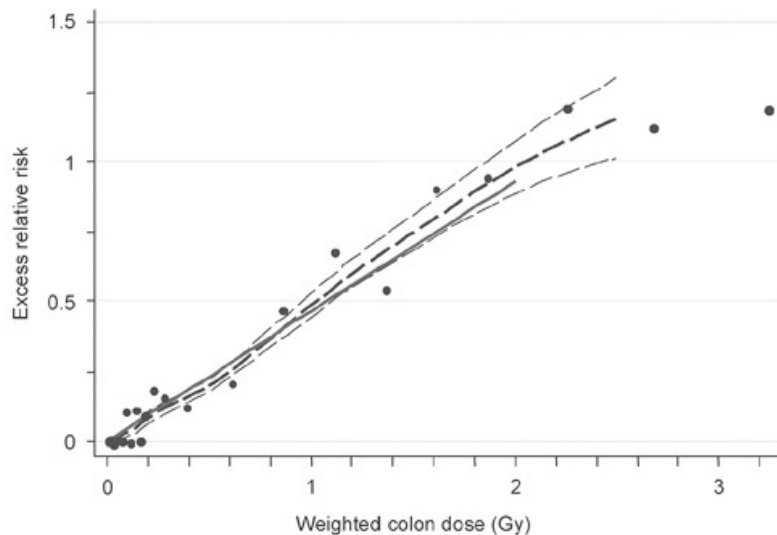
Radiation Health Effects: Late

- **Stochastic (random)** –
 - Health effects that occur randomly and for which the probability of the effect occurring, rather than its severity, is assumed to be a linear function of dose **without threshold**.



Radiation Induced Cancer risk

- Data for 4 populations:
 - Japanese atomic bomb survivors
 - Medically exposed populations



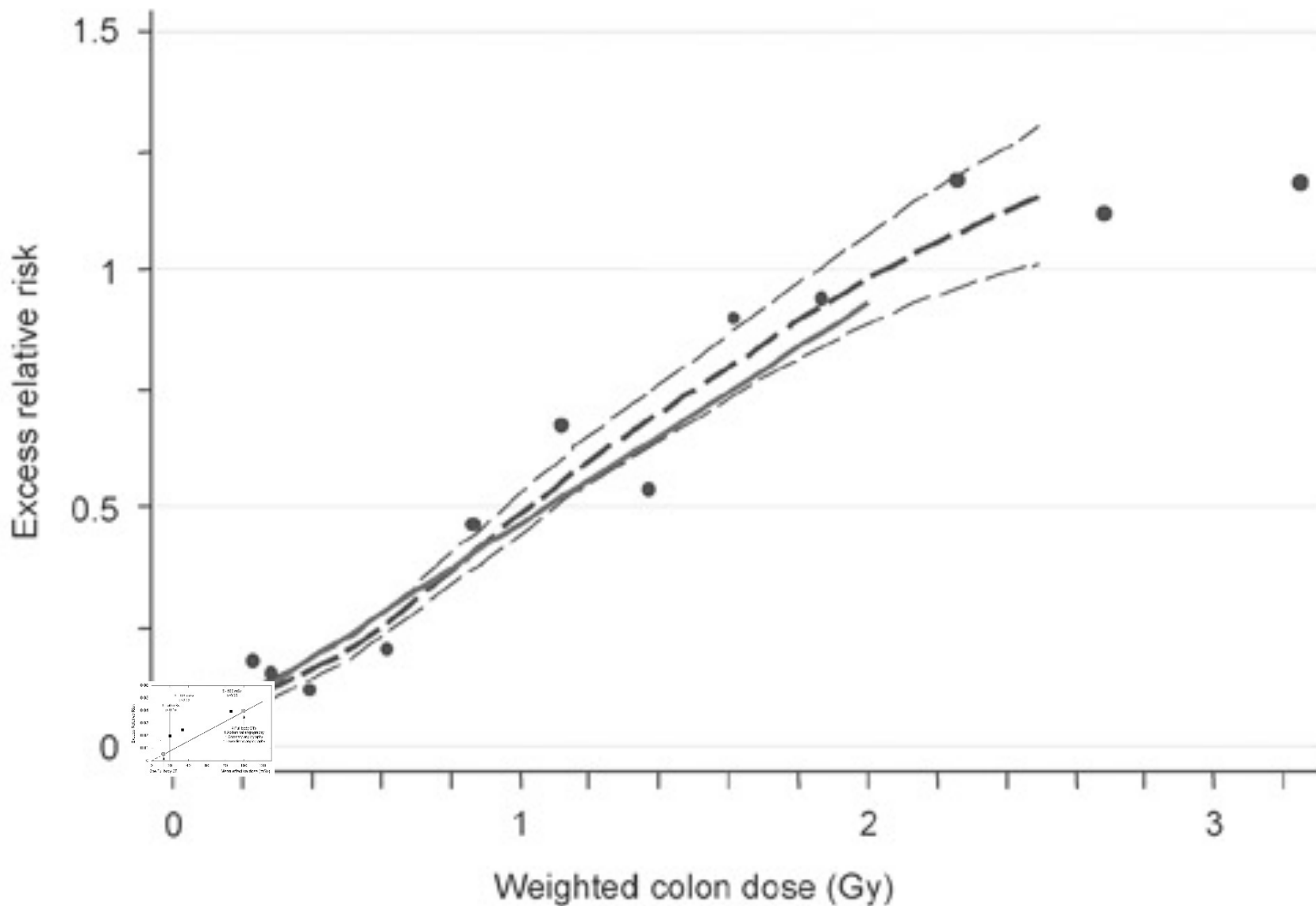
Excess risk of developing solid cancers in LSS, 1958-1998

Weighted colon dose (Gy)	LSS subjects	Cancers		Attributable risk
		Observed	Estimated excess	
0.005 – 0.1	27,789	4,406	81	1.8%
0.1 – 0.2	5,527	968	75	7.6%
0.2 – 0.5	5,935	1,144	179	15.7%
0.5 – 1.0	3,173	688	206	29.5%
1.0 – 2.0	1,647	460	196	44.2%
>2.0	564	185	111	61.0%
Total	44,635	7,851	848	10.7%

https://www.rerf.or.jp/en/programs/roadmap_e/health_effects-en/late-en/cancrisk/



Radiologic Risk v. Natural Cancer Risk



Radiation and children

- Radiation levels required for imaging examinations of children are generally lower than those for adults due to their smaller size
- Radiation-induced cancer mortality risk in children is 3 to 5 times higher than for adults
 - increased organ sensitivity and longer life expectancy (relevant to the long latency that appears to accompany radiation exposure)



Modalities

Bone Morphology or Alignment

- Radiography
- Computed Tomography (CT)
- Magnetic Resonance Imaging (MRI)
- Tc-99m methyl diphosphonate (MDP) Bone Scintigraphy

Bone Mineralization or Health

- Dual-energy X-ray absorptiometry (DEXA)
- Single x-ray absorptiometry (SXA)
- Vertebral fracture assessment (VFA)
- Quantitative Computed Tomography (QCT)
- Peripheral Quantitative Computed Tomography (pQCT)
- Trabecular Bone Score (TBS)
- Peripheral ultrasound (QUS)



Modalities

Bone Morphology or Alignment

- Radiography
- Computed Tomography (CT)
- Magnetic Resonance Imaging (MRI)
- ~~Tc-99m methyl diphosphonate (MDP) Bone Scintigraphy~~

Bone Mineralization or Health

- Dual-energy X-ray absorptiometry (DEXA)
- ~~Single x-ray absorptiometry (SXA)~~
- Vertebral fracture assessment (VFA)
- Quantitative Computed Tomography (QCT)
- Peripheral Quantitative Computed Tomography (pQCT)
- Trabecular Bone Score (TBS)
- Peripheral Ultrasound (QUS)



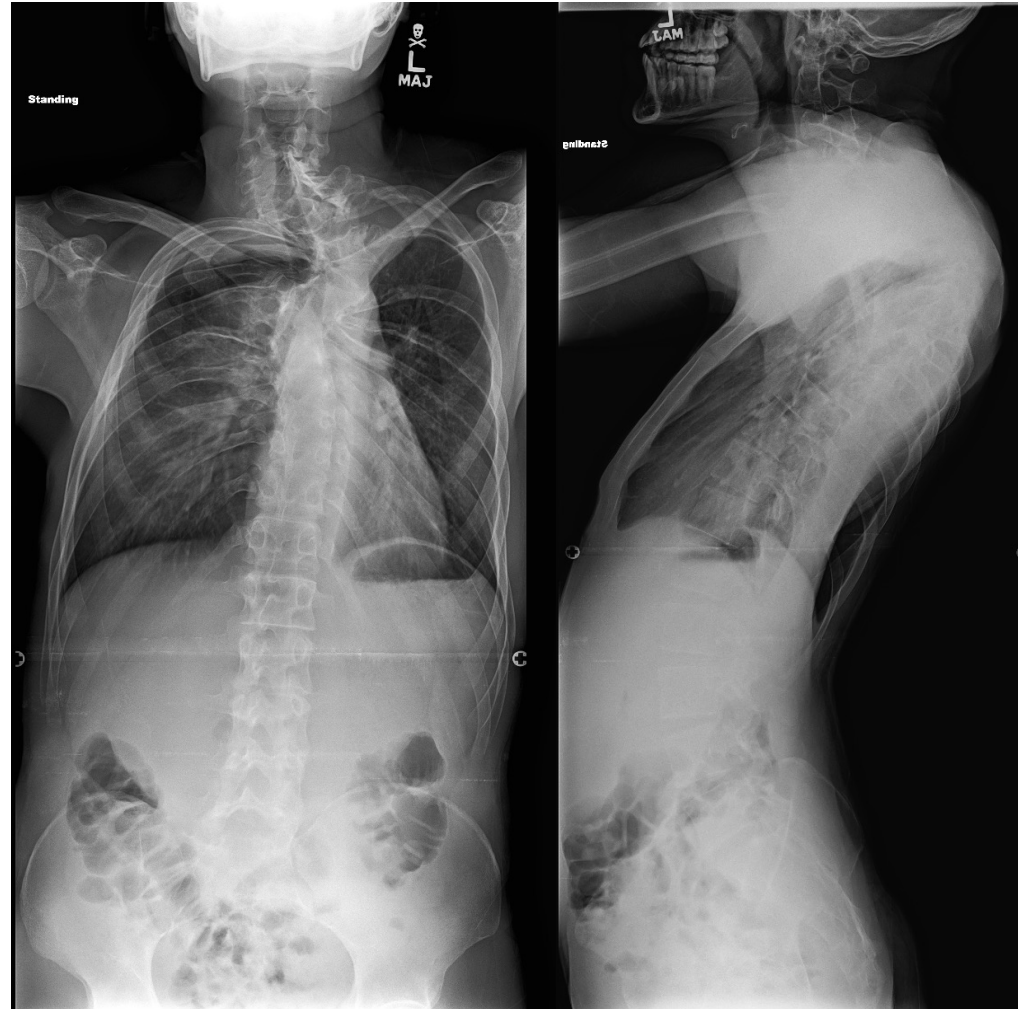Bone Morphology or Alignment



Response Evaluation In Neurofibromatosis Schwannomatosis
INTERNATIONAL COLLABORATION

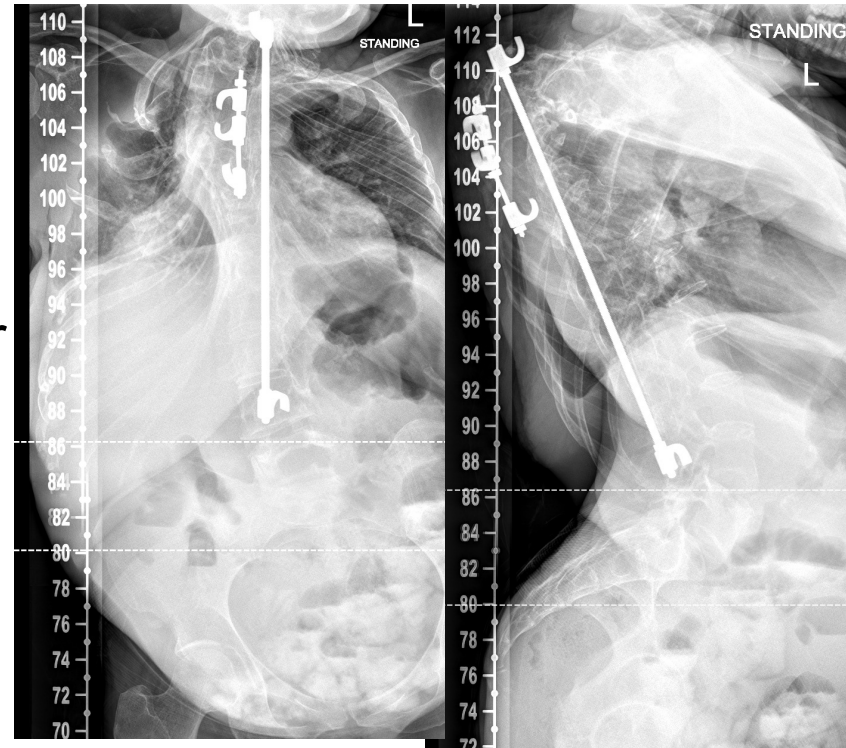
Radiography

- **Role:** **Primary** imaging modality employed for diagnosis & classification of scoliosis
 - Evaluation of severity
valuating severity
 - Monitoring progression
 - Risser index, a measure of the degree of iliac apophysis ossification and a marker for both skeletal maturity and potential curve progression
 - Assessment of treatment response



Radiography

- **Technique:**
 - PA
 - instead of AP technique to reduce breast dose
 - Lateral only on initial encounter
 - Employed only for alterations in sagittal balance
 - Low dose
 - CR & DR >>> cassette radiography



Biplanar stereoradiography (EOS[®])

- **Technique:** EOS[®] takes simultaneous AP/lateral 2D images of the whole body and can be utilized to perform 3D reconstruction
- **Dose:** Relatively low dose of radiation
 - 50–80 % less than conventional X-rays
- **Image quality:** similar to CR



Yeung KH, Man GCW, Lam TP, Ng BKW, Cheng JCY, Chu WCW. Accuracy on the preoperative assessment of patients with adolescent idiopathic scoliosis using biplanar low-dose stereoradiography: a comparison with computed tomography. BMC Musculoskelet Disord. 2020 Aug 18;21(1):558.

Garg B, Mehta N, Bansal T, Malhotra R. EOS[®] imaging: Concept and current applications in spinal disorders. J Clin Orthop Trauma. 2020 Sep-Oct;11(5):786-793.

Biplanar stereoradiography (EOS[®])

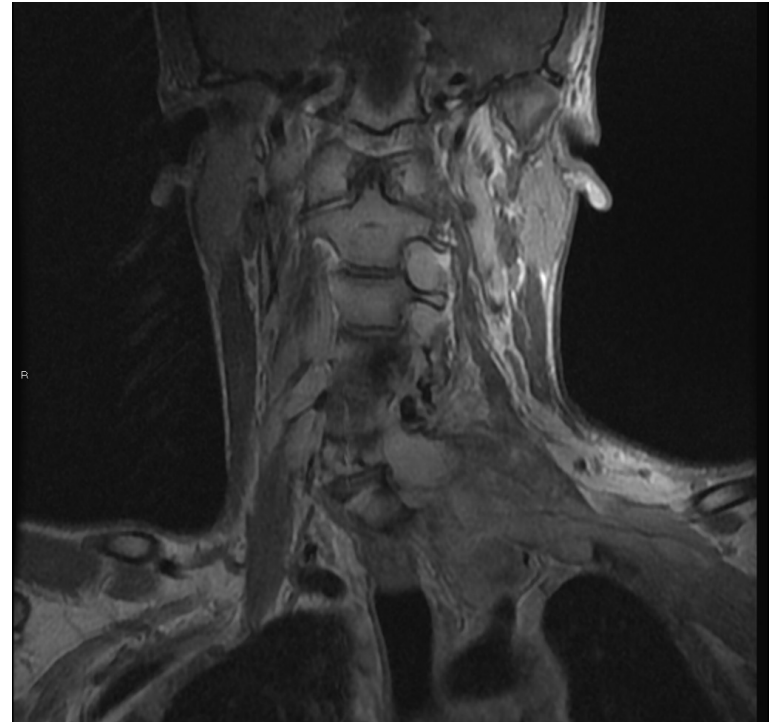
- **Diagnostic accuracy:** similar to 2D measurements
- **Precision of 2D measurements:** excellent inter-observer reproducibility and intraobserver repeatability (ICC > 0.8)
- **2D vs 3D EOS[®]:** very high intra-observer repeatability for Cobb angle, thoracic kyphosis, and lumbar lordosis, and better interobserver reproducibility than 2D methods.

Yeung KH, Man GCW, Lam TP, Ng BKW, Cheng JCY, Chu WCW. Accuracy on the preoperative assessment of patients with adolescent idiopathic scoliosis using biplanar low-dose stereoradiography: a comparison with computed tomography. BMC Musculoskelet Disord. 2020 Aug 18;21(1):558.

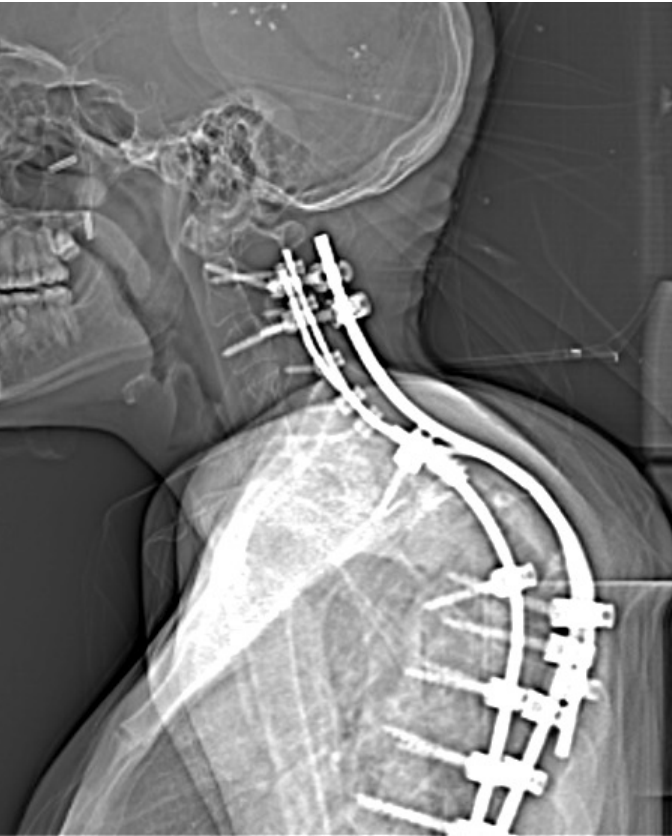


Magnetic Resonance Imaging

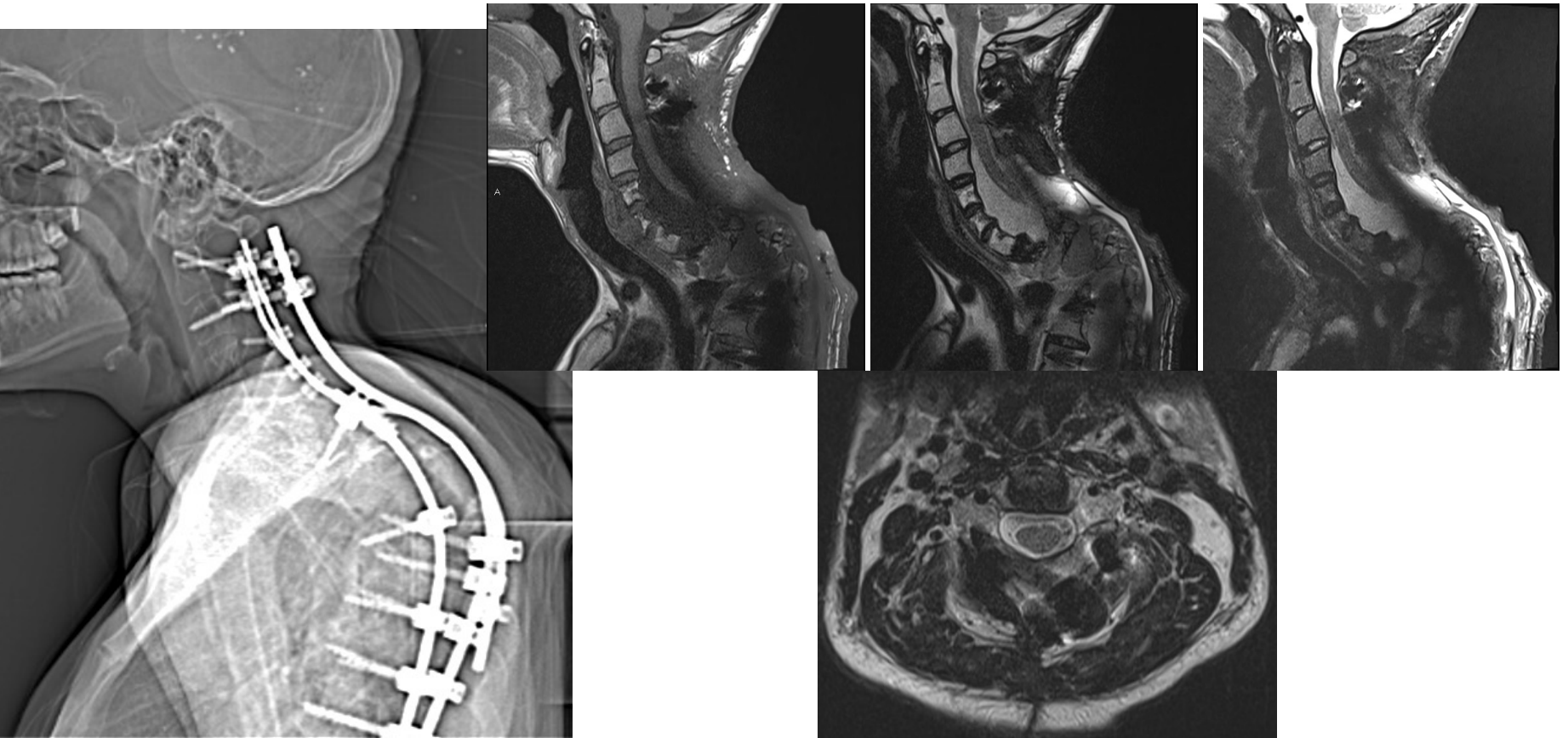
- **Role:** Detect and characterize intraspinal abnormalities
- **Technique:**
 - 2D: Sagittal T1, T2, STIR and Axial T2 +/- T2
 - 3D: STR SPC – coronal acquisition
 - NO IV CONTRAST



MRI

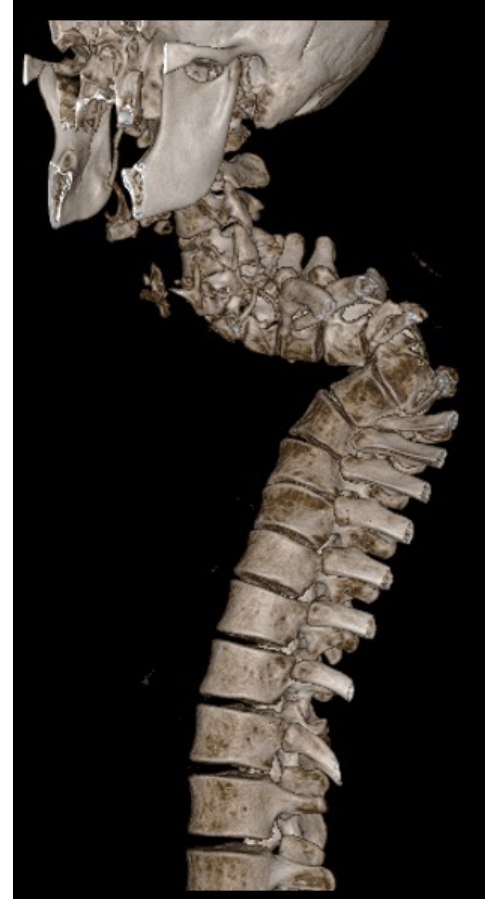

MRI using metal artifact reduction sequences



Computed Tomography

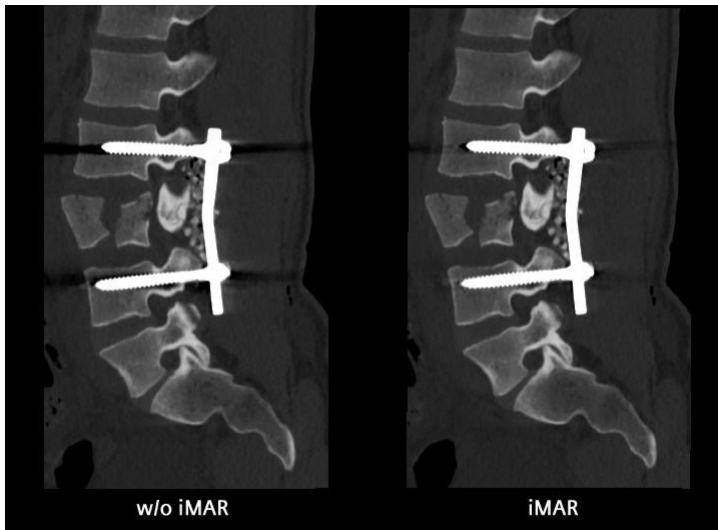
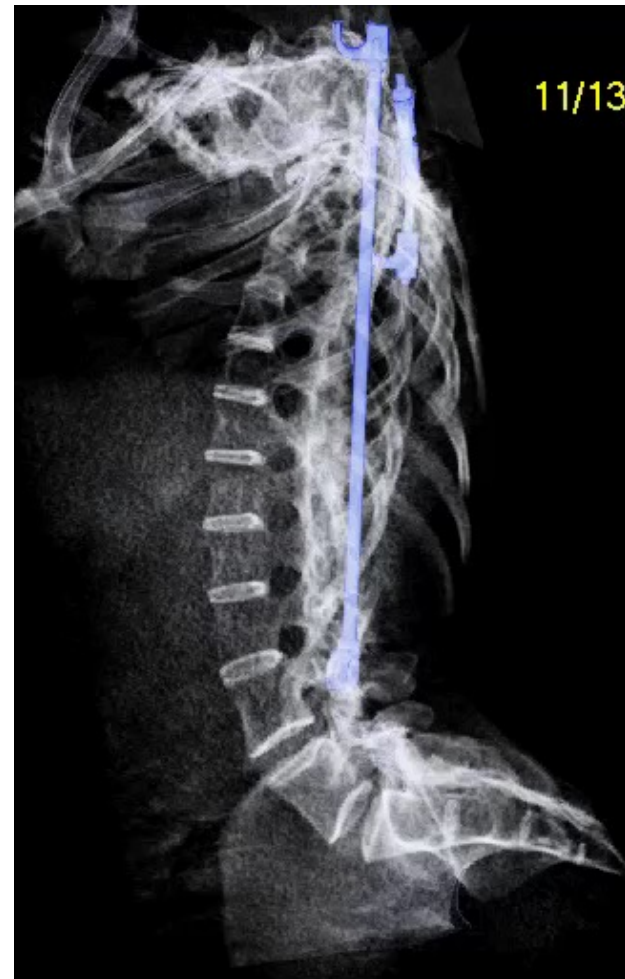- **Role:** Characterize and define osseous anatomy or osseous tumor (osteoid osteoma)
- **Technique:**
 - Low-dose protocols
 - NO IV CONTRAST



CT with metal artifact reduction

- **Technique:**

- Low-dose protocols
 - The existing literature suggests that there is **no increase in radiation exposure** when DECT protocols, based on DSCT technology, are used instead of single-energy techniques.
- **NO IV CONTRAST**



Bone Mineralization or Health



Response Evaluation In Neurofibromatosis Schwannomatosis
INTERNATIONAL COLLABORATION

Dual-Energy X-ray Absorptiometry

- **Role:** **Primary** imaging modality employed for diagnosis
 - Accurately and precisely measures BMD at specific sites
 - the lumbar spine, hip, and distal forearm
 - Quantitative T-score
 - T-scores = -1.0 to -2.4 \rightarrow Low bone mass or osteopenia
 - T-scores ≤ -2.5 \rightarrow Osteoporosis

Li N, Li XM, Xu L, Sun WJ, Cheng XG, Tian W. Comparison of QCT and DXA: Osteoporosis Detection Rates in Postmenopausal Women. Int J Endocrinol. 2013;2013:895474.



Dual-Energy X-ray Absorptiometry

- **Technique:**

- Projectional **x-ray** based technology
- Accurately and precisely measures BMD at specific sites
 - the lumbar spine, hip, and distal forearm
- Quantitative T-score
 - T-scores = -1.0 to -2.4 → Low bone mass or osteopenia
 - T-scores ≤ -2.5 → Osteoporosis



Vertebral fracture assessment (VFA)

- Feature of DXA scanners in which lateral thoracic and lumbar spine images are obtained and screened for fracture
 - The detection of fractures in some patients with osteopenia is a predictor of future fractures and allows for their risk re-stratification and potential initiation of pharmacotherapy

Schmidt T et al. A retrospective analysis of bone mineral status in patients requiring spinal surgery. BMC Musculoskelet Disord. 2018. 13;19(1):53.



Quantitative Computed Tomography (QCT)

- **Technique:**

- Can be performed on the vast majority of commercially available CT scanners
 - provided they include densitometry analysis software and a calibration phantom



Kinsella S et al. Comparison of single CT scan assessment of bone mineral density, vascular calcification and fat mass with standard clinical measurements in renal transplant subjects: the ABC HeART study. BMC Nephrol. 2015 Nov 11;16:188.

Quantitative Computed Tomography

- **Role:**

- Provides a **volumetric BMD** (in contrast to the area BMD of the DXA, which is based on a 2-D projectional area measurement)
- Quantitative T-score
 - BMD values from 120–80 mg/mL → Low bone mass or osteopenia
 - BMD values \leq 80 mg/mL → Osteoporosis



Quantitative Computed Tomography

- **Role:** Specific cases in which QCT >> DXA include:
 - Extremes in body height (ie, very large and very small patients)
 - BMI >35 kg/m²
 - Patients with extensive degenerative disease of the spine
 - A **clinical care or trial setting** that requires increased sensitivity to small changes in trabecular bone density (parathyroid hormone and glucocorticoid treatment monitoring)



Peripheral Quantitative Computed Tomography (pQCT)

- **Technique:**

- Can be performed on the vast majority of commercially available CT scanners
 - provided they include densitometry analysis software and a calibration phantom
- Scans of the forearm/tibia
- **Lower dose than cQCT**
- May predict hip fractures (but not spine) in post-menopausal women
 - But perhaps not men

Link TM. Osteoporosis imaging: state of the art and advanced imaging. Radiology. 2012 Apr;263(1):3-17.










Risk of Radiation – Bone Morphology

Modality	Appropriateness Category	Relative Radiation Level	Adult Effective Dose Estimate Range	Pediatric Effective Dose Estimate Range
Scoliosis Series (XR complete spine)	Usually Appropriate	☠☠☠	1-10 mSv	0.3-3 mSv
MRI whole spine without (Non-con)	Usually Appropriate	0	0 mSv	0 mSv
CT spine area of interest (Non-con)	Usually Appropriate	☠☠☠☠	10-30 mSv	3-10 mSv
Bone scan complete spine	Usually NOT Appropriate	☠☠☠☠	10-30 mSv	3-10 mSv

<https://acsearch.acr.org/docs/3101564/Narrative/>



Risk of Radiation – Bone Health

Modality	Appropriateness Category	Relative Radiation Level	Adult Effective Dose Estimate Range	Pediatric Effective Dose Estimate Range
DEXA scan (L spine/hips)	Usually Appropriate		<0.1 mSv	<0.3 mSv
DEXA scan (forearm)	Maybe Appropriate		<0.1 mSv	<0.3 mSv
VFA derived from DEXA	Maybe Appropriate		<0.1 mSv	<0.3 mSv
QCT (L spine/hips)	Maybe Appropriate		1-10 mSV	0.3-3 mSv
pQCT (distal forearm)	Usually NOT Appropriate		<0.1 mSv	<0.3 mSv
QUS	Usually NOT Appropriate		0 mSv	0
SXA (distal forearm)	Usually NOT Appropriate		<0.1 mSv	<0.3 mSv

<https://acsearch.acr.org/docs/3101564/Narrative/>



Cumulative Exposure

- N=271 with AIS
 - mean age = 15
- Mean spine XRs = 8
- Estimated mean effective dose delivered ~ 21 mSv
 - Equating to an additional cancer risk of 0.27-0.45%.

› Spine Deform. 2021 Mar 3. doi: 10.1007/s43390-021-00314-6. Online ahead of print.

Estimated cumulative X-ray exposure and additional cancer risk during the evaluation and treatment of scoliosis in children and young people requiring surgery

P R Loughenbury ¹, S L Gentles ², E J Murphy ², J E Tomlinson ², V H Borse ², R A Dunsmuir ², N W Gummerson ², P A Millner ², A S Rao ², E Rowbotham ², A L Khan ²



Evolution of Radiation Dose

Table 1

Patient data showing similar age and sex distribution between both cohorts.

	Intra-individual analysis	Inter-individual analysis
Patients included	4059	203
Sex	69.4% female	63.6% female
Age	61.3 ± 13.6 a	59.8 ± 13.9 a

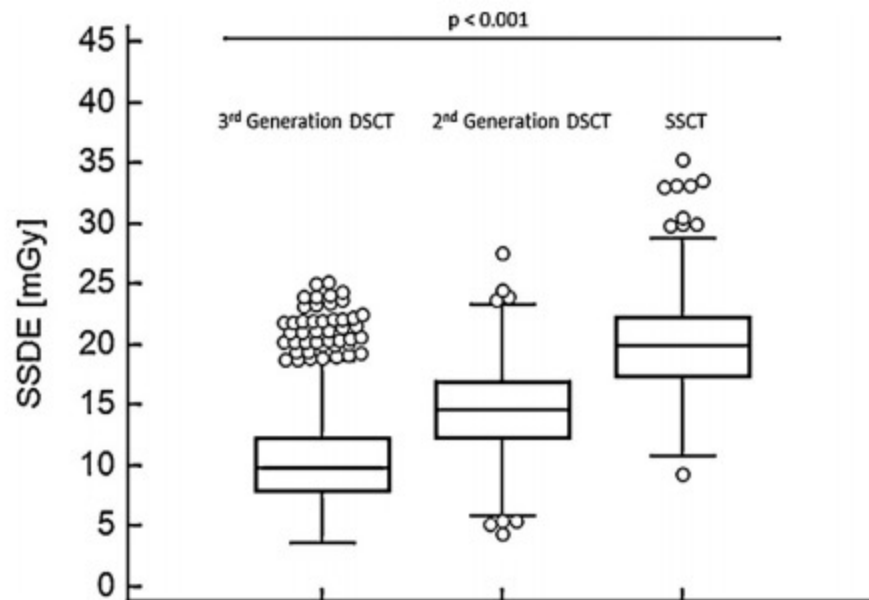
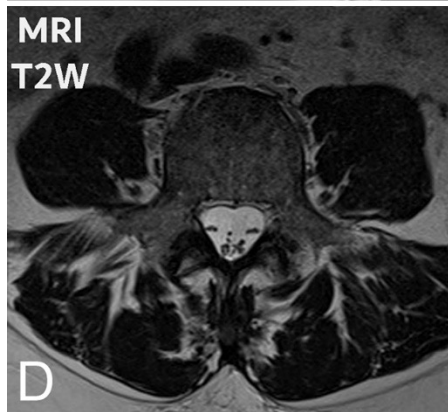
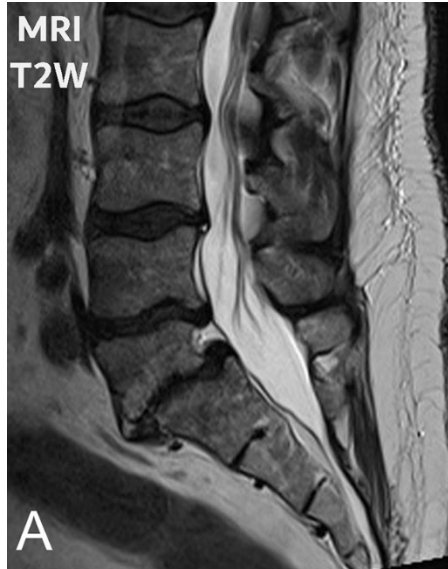

Fig. 2. Inter-observer box plot statistics of 4059 patients, retrieved by the automatic tracking and monitoring program, who have undergone a WBCT on the 3rd- and 2nd-generation DSCT and SSCT, displaying the decrease of radiation dose as a function of newer CT-generation.



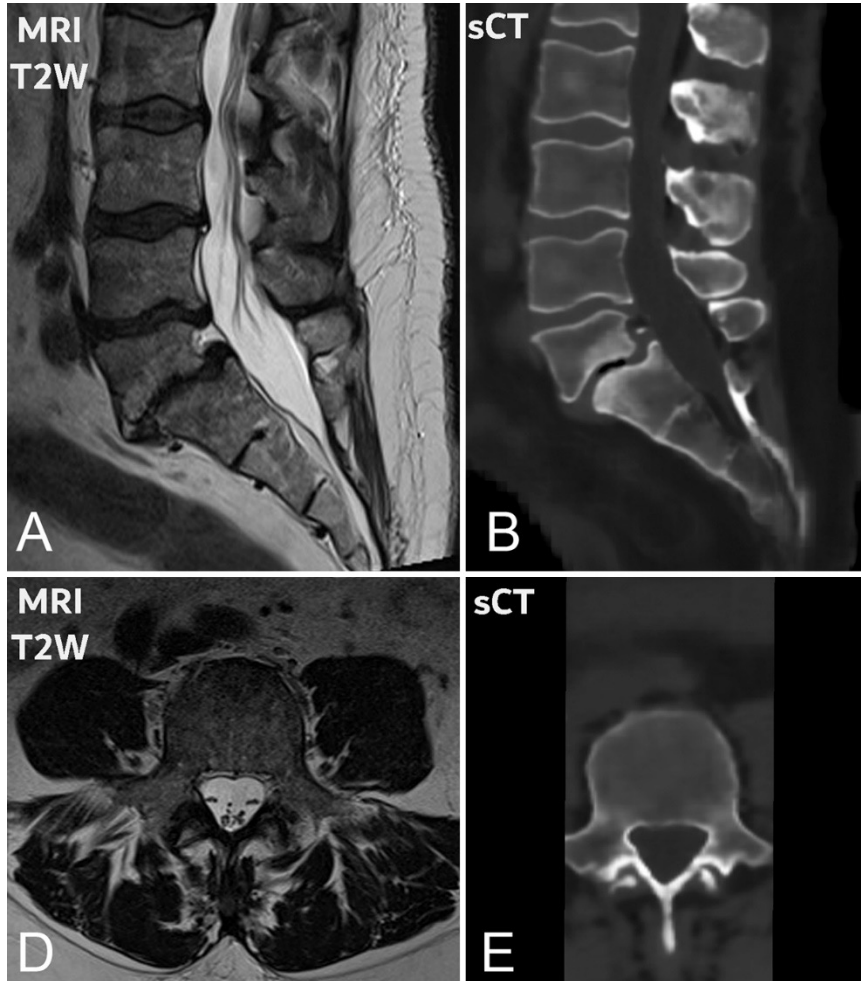
Future!



Sollmann N, Löffler MT, Kronthaler S, Böhm C, Dieckmeyer M, Ruschke S, Kirschke JS, Carballido-Gamio J, Karampinos DC, Krug R, Baum T. MRI-Based Quantitative Osteoporosis Imaging at the Spine and Femur. *J Magn Reson Imaging*. 2020 Jun 25.

Staatjes VE, Seevinck PR, Vandertop WP, van Stralen M, Schröder ML. Magnetic resonance imaging-based synthetic computed tomography of the lumbar spine for surgical planning: a clinical proof-of-concept. *Neurosurg Focus*. 2021 Jan;50(1):E13.

Future!

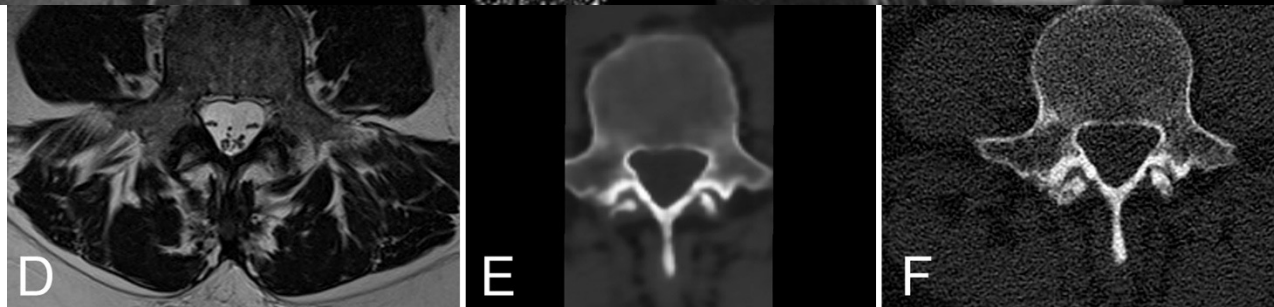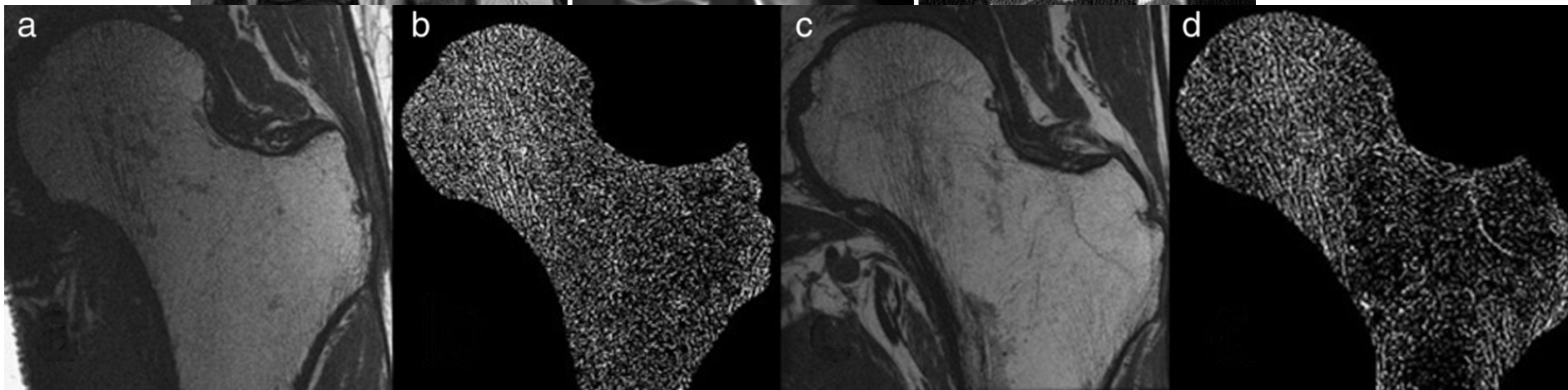
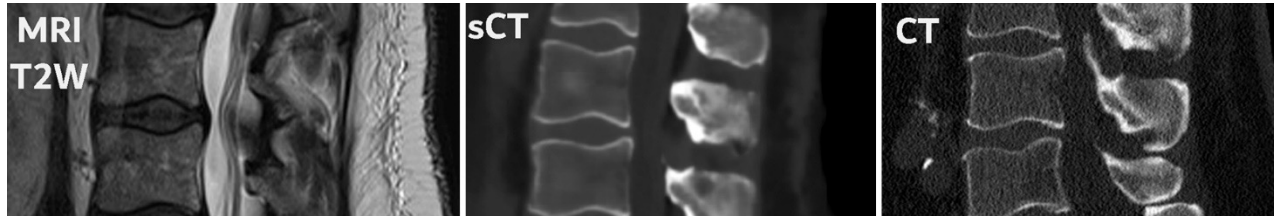


Sollmann N, Löffler MT, Kronthaler S, Böhm C, Dieckmeyer M, Ruschke S, Kirschke JS, Carballido-Gamio J, Karampinos DC, Krug R, Baum T. MRI-Based Quantitative Osteoporosis Imaging at the Spine and Femur. *J Magn Reson Imaging*. 2020 Jun 25.

Staatjes VE, Seevinck PR, Vandertop WP, van Stralen M, Schröder ML. Magnetic resonance imaging-based synthetic computed tomography of the lumbar spine for surgical planning: a clinical proof-of-concept. *Neurosurg Focus*. 2021 Jan;50(1):E13.



Future!



Sollmann N, Löffler MT, Kronthaler S, Böhm C, Dieckmeyer M, Ruschke S, Kirschke JS, Carballido-Gamio J, Karampinos DC, Krug R, Baum T. MRI-Based Quantitative Osteoporosis Imaging at the Spine and Femur. *J Magn Reson Imaging*. 2020 Jun 25.

Staatjes VE, Seevinck PR, Vandertop WP, van Stralen M, Schröder ML. Magnetic resonance imaging-based synthetic computed tomography of the lumbar spine for surgical planning: a clinical proof-of-concept. *Neurosurg Focus*. 2021 Jan;50(1):E13.

ALARA Designs



Time • Distance • Shielding



image
gently®



Thank you
sahlawa1@jhmi.edu



Response Evaluation In Neurofibromatosis Schwannomatosis
INTERNATIONAL COLLABORATION